



Characterization of neoplastic and cystic abdominal masses in children, reporting to the government tertiary care center in Vishakhapatnam – A longitudinal, prospective study

Naga Karthik Garikapatri¹, Vasanth Dunna², Harini Konakyana³, Kameshwari Kolachana³

¹Department of Paediatric Surgery, KIMS Super Specialty Hospital, Amalapuram, Andhra Pradesh, India, ²Department of General Surgery, KIMS Super Specialty Hospital, Amalapuram, Andhra Pradesh, India, ³Department of Paediatric Surgery, Andhra Medical College, Vishakhapatnam, Andhra Pradesh, India

Keywords:

Abdominal mass, malignant neoplasms, pediatric neoplasms, pelvi-ureteric junction obstruction, Wilm's tumor

Correspondence:

Dr. Naga Karthik Garikapatri, Department of Paediatric Surgery, KIMS Super Specialty Hospital, Amalapuram - 533201, Andhra Pradesh, India.
Phone: 91-9640790427.
E-mail: nkarthikg1982@gmail.com

Received: 28 August 2019;

Accepted: 29 September 2019

doi: 10.15713/ins.jcri.280

Abstract

Aim: This study aimed to characterize the neoplastic and cystic abdominal masses in children, reporting to the tertiary care center in Vishakhapatnam.

Objectives: The objectives include reporting on the age of presentation, sex distribution, incidence, history, presenting features, organs involved, investigations, resectability of tumor, operative procedures, post-operative status, and recurrence. Additionally for malignant swellings, the stages of presentation, adjuvant chemotherapy, or radiotherapy are reported.

Materials and Methods: A longitudinal, prospective study was conducted from 2014 to 2017 in which 370 participants were recruited by consecutive systematic sampling. The children presenting with abdominal mass to the department of pediatric surgery, below the age of 13 were included in the study. Abdominal masses having acute presentations and hepatosplenomegalies due to medical causes were excluded from the study. Descriptive statistics were used to report on various stated objectives.

Results: Wilm's tumor was the most common malignant tumor, and pelvic-ureteric junction (PUJ) obstruction was the most common benign condition causing abdominal mass. The other abdominal masses are reported in terms of stated objectives.

Conclusion: Wilm's tumor was the most common malignant tumor. The incidence of advanced and metastatic tumors is considerably higher with tumors being reported at Stage 3 or Stage 4 in initial presentations. PUJ obstruction was the most common cause of benign renal masses, with half of the cases being detected antenatally and had improved renal function post-pyeloplasty. Masses involving the gastrointestinal tract and those proved benign in histology had a good prognosis. The prognosis of malignant tumors could only be commented by further studies with higher samples and strict follow-up.

Clinical Significance: The abdominal swellings in children are reported when parents find a notable change in children. Awareness, education, and parental motivation may help in the early diagnosis of swellings that could be initial stages of fatal diseases. The importance of a child's age as a prognostic factor must be considered by the clinicians while planning surgical treatments.

Introduction

The child with an abdominal mass remains to be a challenging problem for the clinicians. It is more often that apart from parent's observations that the child is "acting funny" or is "tired," few symptoms can be elicited. The end result is that the children are brought to the attention of physicians at relatively

advanced stages of their diseases. The majority of children who present with abdominal masses do not have surgical disease but rather hepatomegaly due to leukemia or splenomegaly of portal hypertension. In those needing surgical intervention, the majority of masses are retroperitoneal. The retroperitoneum is a unique inaccessible space in the infant and child, wherein all benign and malignant tumors of the kidneys and adrenal glands

such as the neuroblastomas, lymphomas, rhabdomyosarcomas, sporadic teratomas, and rare lipomas or liposarcoma can originate.

In newborns, two-thirds of the patients with the presenting sign “abdominal mass” have either hydronephrosis or polycystic kidney disease. Urinary retention, renal vein thrombosis, and hydrometrocolpos must also be considered in this age group. In children between 1 and 12 months of age, neuroblastomas become more frequent and nephroblastomas start to appear. However, in children over 1 year of age, malignant neoplasms account for more than half of the abdominal masses. Considering these facts, it becomes all the more imperative for an earlier diagnosis assisted by discerning investigative tools to bring about the treatment and therefore better chances of survival and life expectancy. This study aims to report on various abdominal masses that reported to the Pediatric Surgery Department of the Andhra Medical College and King George Hospital, Vishakhapatnam, Andhra Pradesh, India.

Methodology

This study was approved by the Institutional Ethical Committee and conducted in the Department of Pediatric Surgery, Andhra Medical college and King George Hospital, under NTR University of Health Sciences. The study design was a longitudinal, prospective study as it was conducted from January 2014 to December 2017 in which 370 participants were recruited by the consecutive systematic sampling (a sampling method involving the consideration of every case in the same order as they report if the inclusion/exclusion criteria stated were met). The initial sample was arrived after the study period was terminated based on convincing and was found to be 333. The final sample size of 370 was adjusted from obtained size of 333+37 (calculated from predicted attrition rate of 10% considering a follow-up study). The loss of sample or mortality before the treatment was thus justified for, while those uneventful cases post-surgery/treatment are reported as per the objectives. The children presenting with abdominal mass to the department of pediatric surgery, below the age of 13 were under the inclusion criteria. Abdominal masses having acute presentations and hepatosplenomegalies due to medical causes were excluded from the study. Written informed consent was obtained from the parent in English and local languages. The uncooperative and unwilling participants were subjected to exclusion criteria. This study aimed to evaluate the various parameters of the disease and compare it with national and international parameters obtained from the various studies. The parameters (objectives) reported are the age of presentation, sex distribution, incidence, antenatal history, presenting features, duration of illness, organ involved, investigations, resectability of tumor, operative procedures, post-operative status, and recurrence. Additionally for malignant swellings, the stage of presentation, adjuvant chemotherapy, or radiotherapy were recorded in the study pro forma.

Statistical tests

Descriptive statistics (mean and percentages) were used to report on various stated objectives.

Results

During the study period, we have studied altogether 370 patients (male: 240 and female: 130). Wilm’s tumor was the most common malignant tumor accounting for 90 patients, and pelvi-ureteric junction (PUJ) obstruction was the most common benign condition causing abdominal mass. The distribution of different malignant and benign abdominal masses is shown in Table 1, and the sex distribution of malignant and benign abdominal swellings is presented in Figures 1 and 2, respectively.

A case of child with abdominal swelling managed surgically is shown in Figure 3.

Discussion

During the study period, 370 patients of the mass abdomen were included, of which Wilm’s tumor is the most common malignant tumor, accounting for 56.2% of all intra-abdominal malignant tumors. Others were neuroblastoma (31.2%), hepatoblastoma (6.2%), and congenital mesoblastic nephroma (6.2%) [Figure 1]. According to the standard literature, neuroblastoma is the most common intraabdominal solid tumor. During our study period, Wilm’s tumor is found to be the most common malignant tumor presenting as the mass abdomen. In the benign abdominal masses, hydronephrosis is the most common cause of abdominal mass in children. PUJ abnormalities account for 62.5% of all benign lumps, followed by choledochal cyst (12.5%), pseudocysts of the pancreas (12.5%), duplication cyst of the intestines (6.25%), and hepatic hydatid cyst (6.25%) [Figure 2]. The descriptive statistics and study objectives are discussed for each abdominal swelling briefly.

Table 1: Age distribution of abdominal swellings in children (0–14 years age group)

S. No.	Abdominal swelling	0–1 year	1–7 years	7–14 years	Total
1	Wilms	20	70	-	90
2	Neuroblastoma	10	20	20	50
3	Hepatoblastoma	-	10	-	10
4	Atypical renal tumors	10	-	-	10
5	Teratoma	20	10	-	30
6	Pelvi-ureteric junction obstruction	40	30	20	90
7	Choledochal cyst	-	20	-	20
8	Pseudopancreatic cyst	-	10	10	20
9	Hydatid cyst	-	-	10	10
10	Mesenteric cyst	-	20	-	20
11	Duplication cyst	10	-	-	10

Wilm’s tumor

Wilm’s tumor in our study showed a male preponderance with (M:F ratio of 3.5:1) which is higher in comparison to that observed by Breslow *et al.* (1.4:1).^[1] The age range in our patients was 10 months–4 years. The mean age is 2.3 years for males

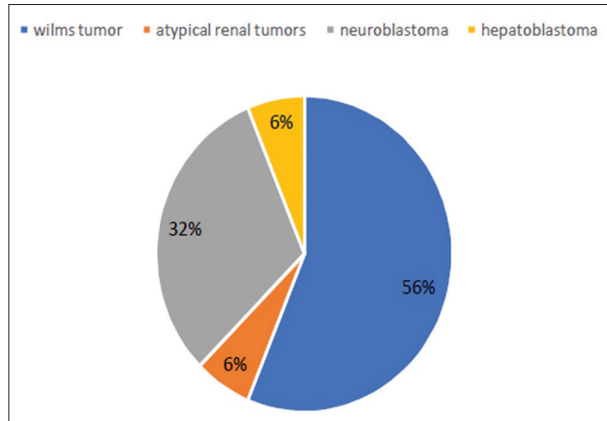


Figure 1: Age distribution of malignant abdominal swellings in children

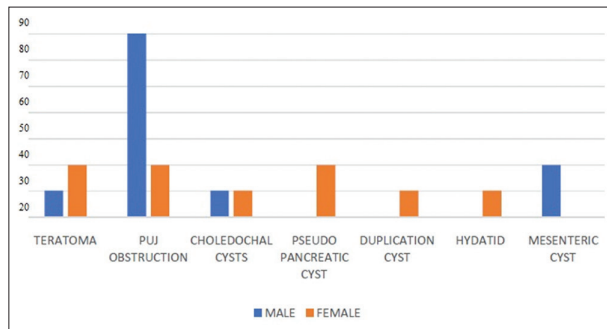


Figure 2: Sex distribution of benign abdominal swellings in children

and 1.5 years for females. According to National Wilm’s tumor study group and Societe Internationale D’oncologie Pediatrique Wilm’s tumor, the age at diagnosis was somewhat younger for boys than in girls (41.5 months vs. 46.9 months for girls). In our study, there were no bilateral synchronous tumors. In our study, the left kidney was involved in 5 patients (55%). Stiller and Parkin. (50% left, 45% right, and 5% bilateral).^[2] Reinhard *et al.* (51.4% - left) have showed left predominance.^[3] WAGR syndrome (Wilms tumor-aniridia syndrome) association was absent in our cases. The most common presentation is a smooth, non-tender, abdominal mass, rarely crossing the midline.

Neuroblastoma

The mean age group of the 50 cases of neuroblastomas studied was 5.5 years. This is quite higher in comparison to the literature (Goodman *et al.* – 17.3 months).^[4] It may be explained by ignorance, illiteracy, and poor socioeconomic status. In our study, male-to-female ratio is 4:1. About 10 patients were <1 year (20%), three patients <7 years (60%), and five patients <15 years (100%). This was as observed by Young *et al.*, which suggest 99% of neuroblastoma present in <15 years of age.^[5] Rapidly growing abdominal mass is the most common presentation in neuroblastoma. In our study, 30 patients were in Stage 3 and 10 patients were in Stage 4. The patients with 4s neuroblastoma patient showed an excellent response to chemotherapy. Hepatomegaly due to liver metastasis also started reducing in size, and the patient did not have any liver metastasis or hepatomegaly by 4th month of age. Neuroblastoma patients did not tolerate chemotherapy well. There were 10 deaths due to the toxicity of chemotherapy.

Hepatoblastoma

Ten cases were recorded during the study period. The patients were staged as PRETEXT Stage 3, and the histology of the tumors was mixed epithelial and mesenchymal type of hepatoblastoma.

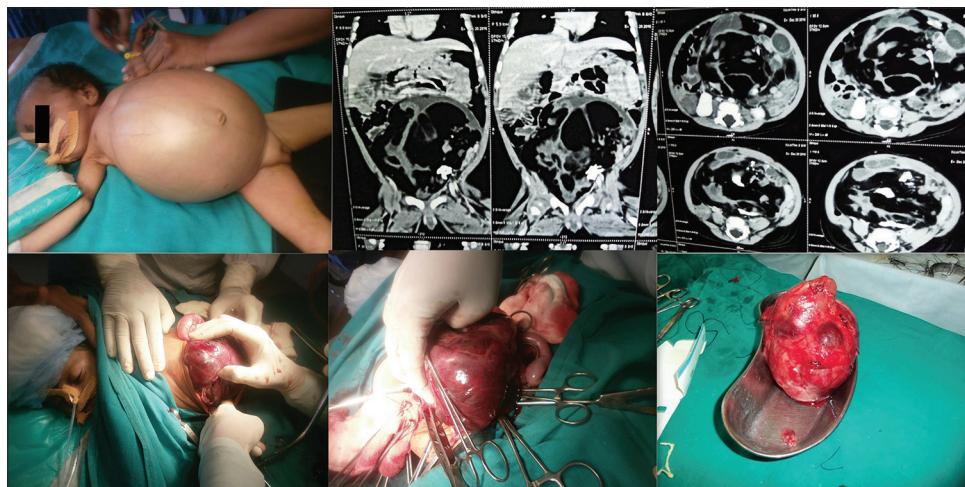


Figure 3: Initial presentation, computed tomography views, intraoperative, and excised specimen of a child with suspected malignant abdominal swelling (Wilm’s tumor)

The prognosis of resectable tumors was good when combined with chemotherapy.

Atypical renal tumors

Atypical renal tumors accounted for around 10% of all malignant renal tumors in our series, which is coinciding with the findings by Chung *et al.*^[6] Surgery was differed in 5 out of 10 patients because of prematurity and low-birth weight. We waited till 1 month of age for the patient to improve in such cases. In patients who developed acute intestinal obstruction, emergency laparotomy with radical nephrectomy was done as needed. Only 5 cases had a good prognosis. Those with poor margins, delayed surgery needing ventilation post-surgery had a bad prognosis (loss of 5 patients).

Benign tumors

PUJ obstruction

In the study period, we got 100 cases of PUJ obstruction with a palpable flank mass. The average male-to-female ratio was 4:1, which is slightly greater than that shown by a study (M:F 2:1) conducted by Johnston *et al.*^[7] According to our series, the left side was 80% more commonly involved than the right side which is more than that reported by Gordon^[8] Nearly 50% of the cases were antenatally detected as suggested in the literature.^[7] The most common presentation was palpable mass (100%), loin tenderness (60%), and urinary tract infection (40%). Overview of presenting symptoms of PUJ obstruction is shown in Figure 4.

Retroperitoneal teratoma

In this study, 30 patients of retroperitoneal teratoma were diagnosed. The male-to-female ratio was 1:2. The literature does not reveal a side or gender predilection.^[9] In the present study, the diagnostic algorithm was (a) palpable solid flank mass and (b) plane radiographs to demonstrate calcifications or formed bony components like teeth (which are pathognomonic), if calcifications are present on radiographs, ultrasound was sufficient to define the extent of the disease. Schey *et al.* have recommended only plain abdominal radiographs and excision of the tumor if the characteristic calcification is demonstrated.^[10] Schey and Vesely have also reported that the presence of bone or teeth on plain film radiographs was most helpful in establishing a preoperative

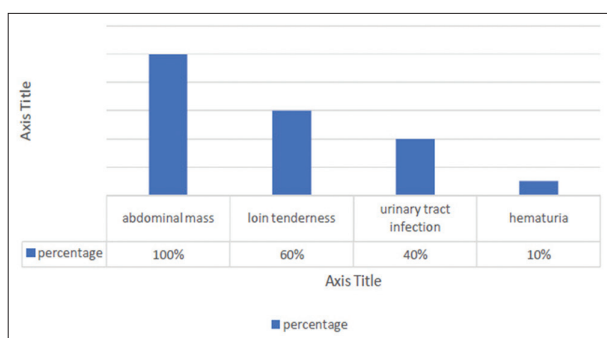


Figure 4: Percentage of symptoms presenting with the most common benign swelling (teratoma)

diagnosis.^[11] Serum alpha-fetoprotein (AFP) was elevated preoperatively in all 30 patients. It returned to normal after the operation. Serum AFP forms a useful marker for monitoring the recurrence. All tumors were mature teratomas in our series. The most important aspect of excision is to remember the close relationship of these tumors with the kidneys. These tumors have a tendency to stretch the renal vessels and also compress the ipsilateral kidney. The renal vessels and the ipsilateral kidney were well preserved in all the patients during the surgery. Benign retroperitoneal teratomas are cured by complete removal. None of the patients in our study group had any recurrence of the tumor on follow-up till the end of the study period.

Choledochal cyst

Twenty patients of the choledochal cyst were detected during the study period. The male-to-female ratio of 1:1, but according to the literature, male-to-female ratio is 4:1.^[12] All the patients had Type 1 cyst. Even literature suggests that the type 1 is the most common (90–95%).^[13]

Pseudopancreatic cyst

Congenital or developmental cysts of the pancreas are rarely reported in the pediatric literature.^[14] These cysts have female preponderance. The most common cause of pseudocysts in children is trauma and infection.^[15] Literature suggests that idiopathic pseudopancreatic cysts occur at <5 years of age.^[16] In our series of 20 patients, the mean age group was 6.5 years. The cause of the pseudocyst was infection in 18 cases and was unknown in 2 cases. Ten patients recovered well with conservative management, and the other 10 underwent a drainage procedure (cystogastrostomy).

Duplication cyst

Ten patients of small intestinal duplication cysts were recorded during the study period, all located in the ileum, at mesenteric border, presenting as intestinal obstruction. All features were typical as in the literature.^[17]

Hydatid cyst

Ten cases of hydatid cysts were recorded during the study period, and it is presented as right-sided abdominal mass, affecting the liver. According to the literature, the peak incidence of echinococcal infection in children is between 5 and 15 years of age. The liver is involved in 60% of the cases, the lung in about 20%, and other organs (the kidney, brain, bone, or muscle) in about 20% of the cases.^[18] The usual presentation is as right upper quadrant pain, mass, and right pleuritic type of chest pain. About a fourth of the patients were asymptomatic.^[19] The patient in this series presented as an asymptomatic right abdominal mass. The recurrence rate after surgical excision of the hepatic hydatid cyst has been reported to range from 1.1% to 9.6%.^[20]

Mesenteric cyst

During the study period, we received 20 cases of mesenteric cysts showed no sex variance, with a mean age of 4.5 years which

is well correlating with what is found in the literature. Both the patients in our series had cysts in the ileal mesentery, and both had to undergo resection anastomosis.

Conclusion

There exists regional and geographical differences that must be considered while characterization of intra-abdominal masses. A total of 11 different abdominal masses were characterized in our study, of which the Wilm's tumor was the most common malignancy. PUJ obstruction was the most common cause of benign renal masses, with half of the cases being detected antenatally. Masses involving the gastrointestinal tract had resolved with a prompt diagnosis and surgical management. Early is watchword for cancers, more so in pediatric patients who fail to report the symptoms. The clinicians must take note of geographic variation of swellings, advice on regular checkups, and parental education which can help saving lives.

References

- Breslow N, Olshan A, Beckwith JB, Green DM. Epidemiology of Wilms tumor. *Med Pediatr Oncol* 1993;21:172-81.
- Stillier CA, Parkin DM. International variations in the incidence of childhood renal tumours. *Br J Cancer* 1990;62:1026-30.
- Reinhard H, Schmidt A, Furtwängler R, Leuschner I, Rube C, Von Schweinitz D, *et al.* Outcome of relapses of nephroblastoma in patients registered in the SIOP/GPOH trials and studies. *Oncol Rep* 2008;20:463-7.
- Goodman MT, Gurney JG, Smith MA, Olshan AF, editors. *Cancer Incidence and Survival among Children and Adolescents: United States Seer Program 1975-1995*. Bethesda, MD: National Cancer Institute, SEER Program; 1999.
- Young JL Jr, Ries LG, Silverberg E, Horm JW, Miller RW. Cancer incidence, survival, and mortality for children younger than age 15 years. *Cancer* 1986;58:598-602.
- Chung EM, Lattin GE Jr, Fagen KE, Kim AM, Pavio MA, Fehringer AJ, *et al.* Renal tumors of childhood: Radiologic-pathologic correlation part 2. The 2nd decade: From the radiologic pathology archives.
- Johnston JH, Evans JP, Glassberg KI, Shapiro SR. Pelvic hydronephrosis in children: A review of 219 personal cases. *J Urol* 1977;117:97-101.
- Gordon I. Diuretic renography in infants with prenatal unilateral hydronephrosis: An explanation for the controversy about poor drainage. *BJU Int* 2001;87:551-5.
- Brodeur GM, Hogarty MD, Mosse YP, Maris JM. Neuroblastoma. In: Pizzo PA, Paplock DG, editors. *Principles and Practice of Oncology*. 6th ed. Philadelphia PA: Lippincott Williams and Wilkins; 2011. p. 886-922.
- Grosfeld JL, Ballantine TV, Lowe D, Baehner RL. Benign and malignant teratomas in children: Analysis of 85 patients. *Surgery* 1976;80:297-305.
- Schey WL, Vesely JJ, Radkowski MA. Shard-like calcifications in retroperitoneal teratomas. *Pediatr Radiol* 1986;16:82-4.
- Alonso-Lej F, Rever WB Jr, Pessagno DJ. Congenital choledochal cyst, with a report of 2, and an analysis of 94, cases. *Int Abstr Surg* 1959;108:1-30.
- Metcalf MS, Wemyss-Holden SA, Maddern GJ. Management dilemmas with choledochal cysts. *Arch Surg* 2003;138:333-9.
- Auringer ST, Ulmer JL, Sumner TE, Turner CS. Congenital cyst of the pancreas. *J Pediatr Surg* 1993;28:1570-1.
- Millar AJ, Rode H, Stunden RJ, Cywes S. Management of pancreatic pseudocysts in children. *J Pediatr Surg* 1988;23:122-7.
- Weizman Z, Durie PR. Acute pancreatitis in childhood. *J Pediatr* 1988;113:24-9.
- Macpherson RI. Gastrointestinal tract duplications: Clinical, pathologic, etiologic, and radiologic considerations. *Radiographics* 1993;13:1063-80.
- Czermak BV, Akhan O, Hiemetzberger R, Zelger B, Vogel W, Jaschke W, *et al.* Echinococcosis of the liver. *Abdom Imaging* 2008;33:133-43.
- Manterola C, Barroso M, Vial M, Bustos L, Muñoz S, Losada H, *et al.* Liver abscess of hydatid origin: Clinical features and results of aggressive treatment. *ANZ J Surg* 2003;73:220-4.
- Magistrelli P, Masetti R, Coppola R, Messia A, Nuzzo G, Picciocchi A. Surgical treatment of hydatid disease of the liver. A 20-year experience. *Arch Surg* 1991;126:518-22.

How to cite this article: Garikapatri NK, Dunna V, Konakyana H, Kolachana K. Characterization of neoplastic and cystic abdominal masses in children, reporting to the government tertiary care center in Vishakhapatnam – A longitudinal, prospective study. *J Adv Clin Res Insights* 2019;6:144-148.

This work is licensed under a Creative Commons Attribution 4.0 International License. The images or other third party material in this article are included in the article's Creative Commons license, unless indicated otherwise in the credit line; if the material is not included under the Creative Commons license, users will need to obtain permission from the license holder to reproduce the material. To view a copy of this license, visit <http://creativecommons.org/licenses/by/4.0/> © Garikapatri NK, Dunna V, Konakyana H, Kolachana K. 2019